

Magnetic Facial Nerve Stimulation in Normal Subjects

Three Groups of Responses

I. RIMPILÄINEN,¹ P. KARMA,^{2,3} H. ESKOLA¹ and V. HÄKKINEN^{1,3}

From the ¹Department of Clinical Neurophysiology, Tampere University Hospital, Tampere, the ²Department of Otolaryngology, Helsinki University Hospital, Helsinki, and the ³Department of Clinical Sciences, University of Tampere, Tampere, Finland

Rimpiläinen I, Karma P, Eskola H, Häkkinen V. Magnetic facial nerve stimulation in normal subjects. Three groups of responses. *Acta Otolaryngol (Stockh) 1992; Suppl 492: 99–102.*

Magnetic stimulation provides a method to stimulate the facial nerve transcranially. With this method, the stimulation can be directed to the intracranial part of the facial nerve, whereas conventional electric stimuli are delivered to a more peripheral part of the nerve. In 40 healthy subjects, ipsilateral responses with latencies of 4.5 ± 0.4 ms were recorded on the nasolabial folds. The latencies were 1.1 ms longer than those elicited at the stylomastoid foramen by electric stimulation. Furthermore, a response with a mean latency of 12 ms (range 10–16 ms) appeared in 6 out of 10 healthy subjects and a polyphasic response with a mean latency of 32 ms in 9 out of 10 of these subjects. Transcranial magnetic stimulation seems to allow the examination of motor conduction through the proximal part of the facial nerve. In addition, the method may give further information concerning the facial activation mechanisms possibly by other central pathways. *Key words: compound muscle action potential, facial nerve activation.*

INTRODUCTION

Transcranial stimulation of the central nervous system has become easier to perform since the introduction of motor cortical stimulation by magnetic stimulator (1). The method has been proven to be safe without significant side effects (2, 3). The technique has also been applied to the facial nerve to measure the responses from the proximal (4–8) or the extracranial part (9) of the nerve. Responses with longer latencies, arising proximal to the facial nerve, have also been reported (10), but the character of these responses is still uncertain. In the present study we examined transcranial magnetic stimulation (TMS) of the facial nerve on its intracranial course and compared the responses with those evoked by electric stimulation at the stylomastoid foramen. Furthermore, we studied responses with prolonged latencies in a small number of patients.

MATERIAL AND METHODS

Subjects

Forty healthy persons (26 females and 14 males without any history of nervous or other disease) were examined. Their median age was 32 years (range = 19–52 years). All the subjects were informed about the examination procedure and gave their consent to the study. The study was approved by the local ethics committee.

Electric stimulation

The examination was conducted with the Medelec Mystro MS 20 EMG-system. The constant current stimuli were rectangular pulses of 200 μ s in duration. The current intensity was increased up to 40 mA, if necessary, to evoke supramaximal responses. Electric stimulation was performed by delivering an electric impulse at the stylomastoid foramen (11).



Magnetic stimulation

Electromagnetic stimulations were delivered using the Cadwell MES-10 magnetic stimulator. The capacitor charged up to 80% of its maximum and then discharged into a circular coil with a diameter of 9 cm. The coil was placed tangentially on the head so that the shield of the coil ring was in contact with the scalp surface. The tip of the coil was always directed anteriorly.

During the stimulation procedures, the subjects were asked to relax and especially to avoid any voluntary contraction of the facial muscles.

The most prominent responses with the same wave form as in electric stimulation at the stylomastoid foramen could be evoked by locating the ring on the parietal area of the skull ($n = 40$). The coil ring was also located 4 cm lateral from the vertex ($n = 10$), where it seemed most easy to evoke responses having longer latencies and smaller amplitudes than those resembling the electrically evoked responses.

A delay of 0.10 ms was detected with our instrumentation, probably arising from the triggering of the magnetic stimulator. This was subtracted from all measured latencies of magnetically induced responses.

Recording

The compound muscle action potentials were recorded with surface electrodes at the nasolabial fold, where, according to our experience, they are most distinguishable. The site of recording the responses was selected as suggested by Fisch (11) and Thomander et al. (12). Responses from the masseter muscle, if they appeared, were excluded.

The latency of the muscle responses was measured from the beginning of the negative deflection (directing upwards). The amplitude was calculated from the start to the peak of the negative deflection. In polyphasic late facial responses the amplitudes were measured from peak to peak.

Statistics

The Student's paired *t*-test was used to compare the significance of differences.

RESULTS

Early facial responses

The mean latency for the ipsilateral electric stimulation of 40 subjects was 3.4 (SD = 0.44) ms on the right side and 3.4 (SD = 0.45) ms on the left. Correspondingly, the mean latency of responses achieved by TMS was 4.5 (SD = 0.40) ms and 4.5 (SD = 0.43) ms (Fig. 1). The mean amplitude of the responses for ipsilateral electric stimulation was 2.3 (SD = 1.0) mV on the right and 2.3 (SD = 0.9) mV on the left. For magnetic stimulation, the mean amplitude was 2.5 (SD = 1.0) mV and 2.7 (SD = 1.2) mV, respectively. The difference of latencies and amplitudes between the sides of stimulation were not significant ($p > 0.05$) (8).

Middle latency facial responses

In 6 of 10 subjects, a response with a mean latency of 12 ms (range = 10–16 ms) and amplitudes ranging from 50 to 250 μ V were achieved either contralaterally (2/6), ipsilaterally (1/6) or bilaterally (3/6) in regard to the side of stimulation (Fig. 2). The response had a tendency to be covered and masked by the early response. Reproducibility of these responses was not good.

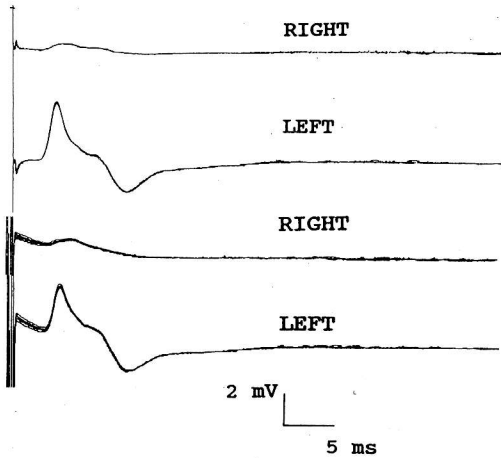


Fig. 1. Bilateral recording showing the early facial responses on the nasolabial folds for left sided series of 5 electric (two upper lines) and magnetic (two lower lines) stimuli. The magnetic stimuli were delivered with the coil positioned on the left parietal area of the skull.

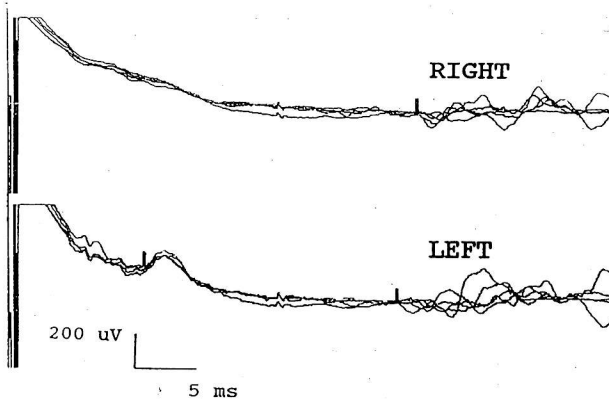


Fig. 2. Bilateral recording on the nasolabial folds for a series of 5 magnetic stimuli, with the stimulating coil placed 4 cm to the left of the vertex. In this subject, the ipsilateral middle latency facial response had a latency of 10.8 ms. The bilateral late facial responses had an ipsilateral latency of 33 ms and a contralateral latency of 35 ms.

Late facial responses

A bilateral polyphasic response appeared in 9 of 10 subjects, with a latency ranging from 28 to 35 ms and amplitude from 50 to 300 μ V (Fig. 2). The response is easy to elicit and reproduce in different series of stimulation.

DISCUSSION

The optimal site for the TMS of the proximal course of the facial nerve was located in a position where the center of the circular coil ring was tangentially in respect to the cranium on the parietal area (8). This corresponds to the observations of earlier studies in this field (6, 13). The responses with longer latencies were, according to our experience, most easily evoked by having the center of the coil ring 4 cm lateral from the vertex.

TMS of the facial nerve has yielded muscle responses with latencies ranging from 4.48 to 5.4 ms (4-7). The transosseal conduction time, calculated as the latency difference between the response for electric stylomastoid stimulation and the TMS, has been 1.2 to 1.3 ms (5, 6, 7). In our stimulation procedure, the latency for TMS was 4.5 ms and the transosseal conduction time 1.1 ms. The difference may be explained by the variation of the sites of registration and by the subtraction of the delay of 0.1 ms in our magnetic stimulation technique. It has been estimated that the site of stimulus is located between the brain stem

and the porus acousticus internus (6, 14). Calculations have also been confirmed by comparing the TMS and direct electric stimulation of the intracisternal segment of the facial nerve (5). The finding is supported by our preliminary findings with a similar preoperative method.

There is considerable variation in the latencies, laterality, and reproducibility of the middle latency facial responses. These responses and their characteristics may reflect the activation of the pathway at various sites, maybe in the intracranial part of the trigeminal nerve, the brain stem, or the facial nerve itself, possibly via reflectory mechanisms.

The wave form of the late facial responses was constantly polyphasic and bilateral. It is thus evident that the response is conveyed by polysynaptic pathways, including the decussating connections. Responses show similarities with the R2 of the blink reflex. Thus it may be assumed that the impulse is generated either in the proximal course of the trigeminal nerve or in the nuclei of the brain stem.

The TMS of the facial nerve is more convenient and better tolerated by the patient than the traditional electrical stimulation at the stylomastoid foramen. The TMS enables a stimulation of the facial nerve on its proximal course and the study of nerve conduction through its bony canal. In addition, the method may contribute to information concerning the various activation mechanisms of the facial nerve.

REFERENCES

1. Barker AT, Jalinous R. Non-invasive magnetic stimulation of human motor cortex. *Lancet* 1985; *i*: 1106-7.
2. Agnew WF, McCreery DB. Considerations for safety in the use of extracranial stimulation for motor evoked potentials. *Neurosurg* 1987; *20*: 143-7.
3. Mano Y, Funakawa I, Nakamura T, Ikoma K, Takayanagi T, Matsui K. The safety of magnetic stimulation. ISEK 7th Congress 20-23 June 1988 (abstract).
4. Maccabee PJ, Amassian VE, Cracco RQ, Cracco JB, Anziska BJ. Intracranial stimulation of facial nerve in humans with the magnetic coil. *Electroencephalogr Clin Neurophysiol* 1988; *70*: 350-4.
5. Rösler KM, Hess CW, Schmid UD. Investigation of facial motor pathways by electrical and magnetic stimulation: sites and mechanisms of excitations. *J Neurol Neurochir Psych* 1989; *52*: 1149-56.
6. Schriefer TN, Mills KR, Murray NMF, Hess CW. Evaluation of proximal facial nerve conduction by transcranial magnetic stimulation. *J Neurol Neurosurg Psychiatr* 1988; *51*: 60-6.
7. Seki Y, Krain L, Yamada T, Kimura Y. Transcranial magnetic stimulation of facial nerve: Recording technique and estimation of the stimulated site. *Neurosurg* 1990; *26*: 286-90.
8. Rimpiläinen I, Eskola H, Häkkinen V, Karma P. Transcranial facial nerve stimulation by magnetic stimulator in normal subjects. *Electromyogr Clin Neurophysiol* 1991; *31*: 259-63.
9. Windmill IM, Martinez SA, Shields CB, Paloheimo M. Magnetically evoked facial nerve potential. *Otolaryngol Head Neck Surg* 1989; *100*: 345-7.
10. Benecke R, Meyer B-U, Schönle P, Conrad B. Transcranial magnetic stimulation of the human brain: Responses in muscles supplied by cranial nerves. *Exp Brain Res*, 1988; *71*: 623-32.
11. Fisch U. Facial paralysis in fractures of the petrous bone. *Laryngoscope* 1974; *84*: 2141-54.
12. Thomander L, Stålberg E. Electroneurography in the prognostication of Bell's palsy. *Acta Otolaryngol (Stockh)* 1981; *92*: 221-37.
13. Murray NMF, Hess CW, Mills KR, Schriefer T, Smith SJM. Proximal facial nerve conduction using magnetic stimulation. *Electroencephalogr Clin Neurophysiol* 1987; *66*: S71 (abstract).
14. Moller AR, Jannetta PJ. Hemifacial spasm: Results of electrophysiologic recording during microvascular decompression operations. *Neurology* 1985; *35*: 969-74.

Address for correspondence: I. Rimpiläinen, Department of Clinical Neurophysiology, Tampere University Central Hospital, SF-33520 Tampere, Finland